

Abdominal Aortic Aneurysm

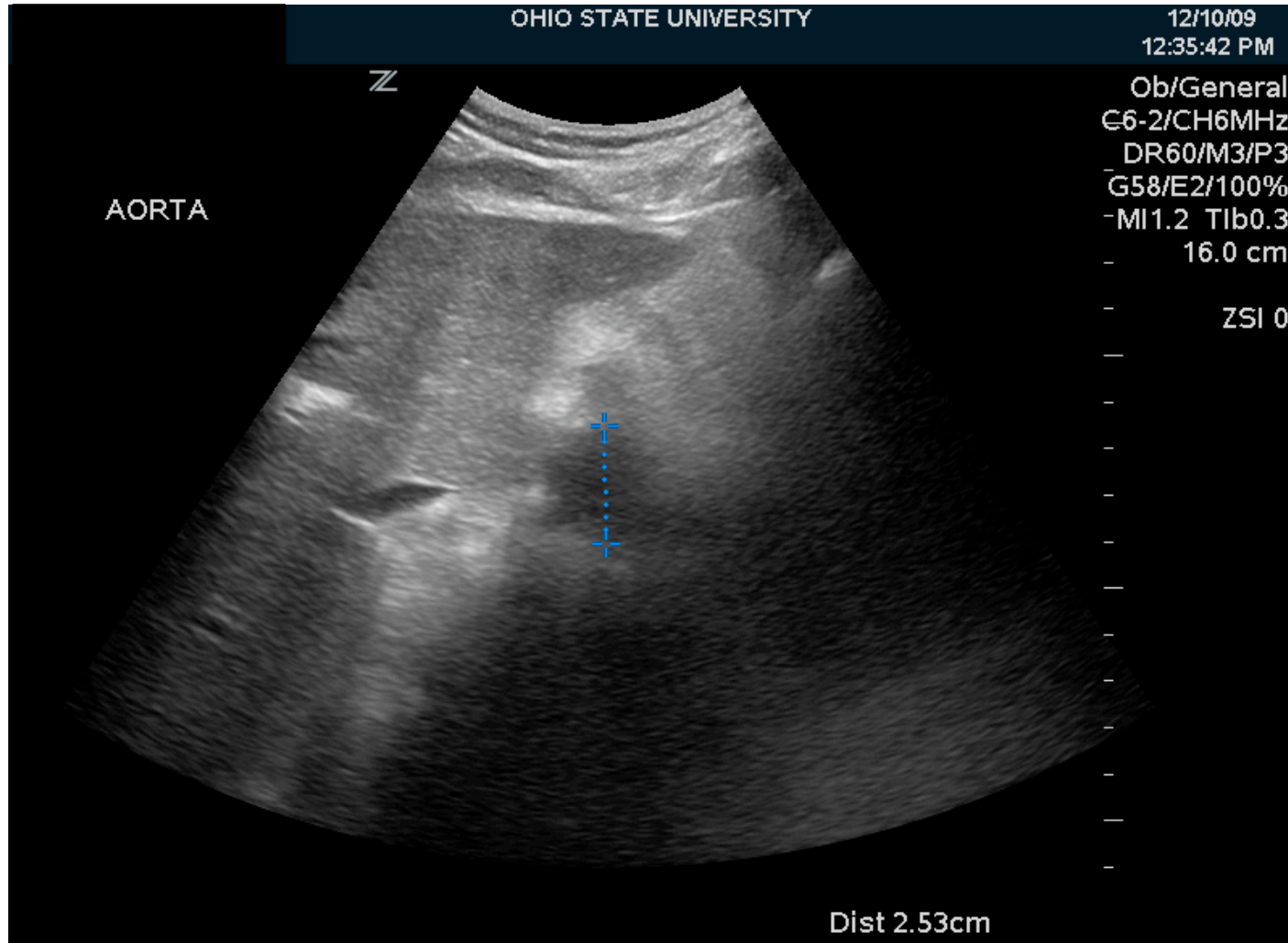
By: Nancy Liao

68-year-old male with history of small cell lung cancer, atrial fibrillation, CHF, coronary artery disease, COPD, AAA, and pancreatitis presented to the ED by EMS with complaints of decreased PO for 3 days and nausea/vomiting. He also reports one presyncopal episode while going from sitting to standing. EMS reported blood pressure at 108/66 on arrival with a heart rate of 86.

During his work up an aortic ultrasound exam was performed which demonstrated his previously known abdominal aortic aneurysm.

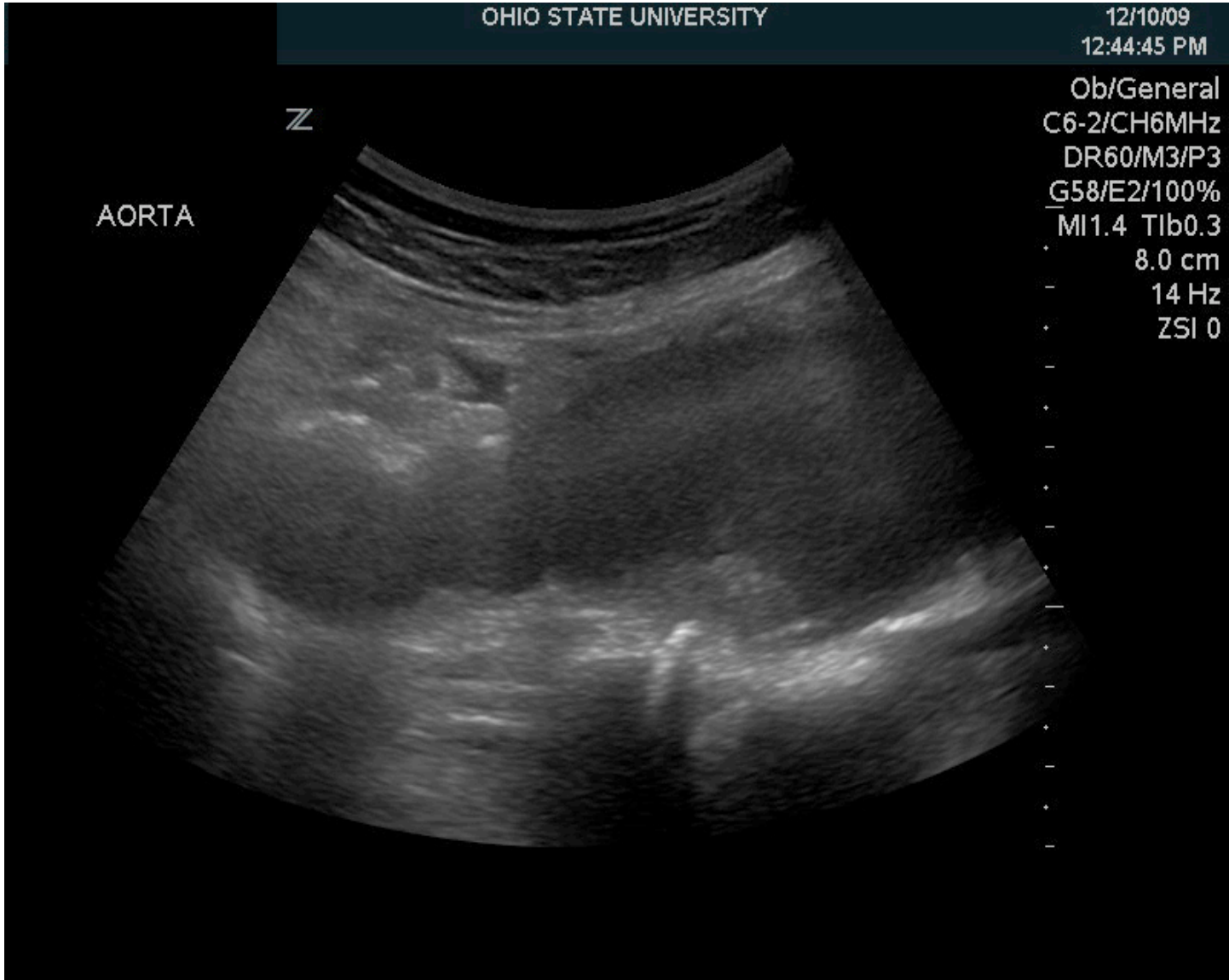
Clinical indication of bedside Aorta U/S exam (suspected leaking or ruptured AAA): abdominal pain, hypotension, syncope, flank pain

Aortic Lumen Diameter

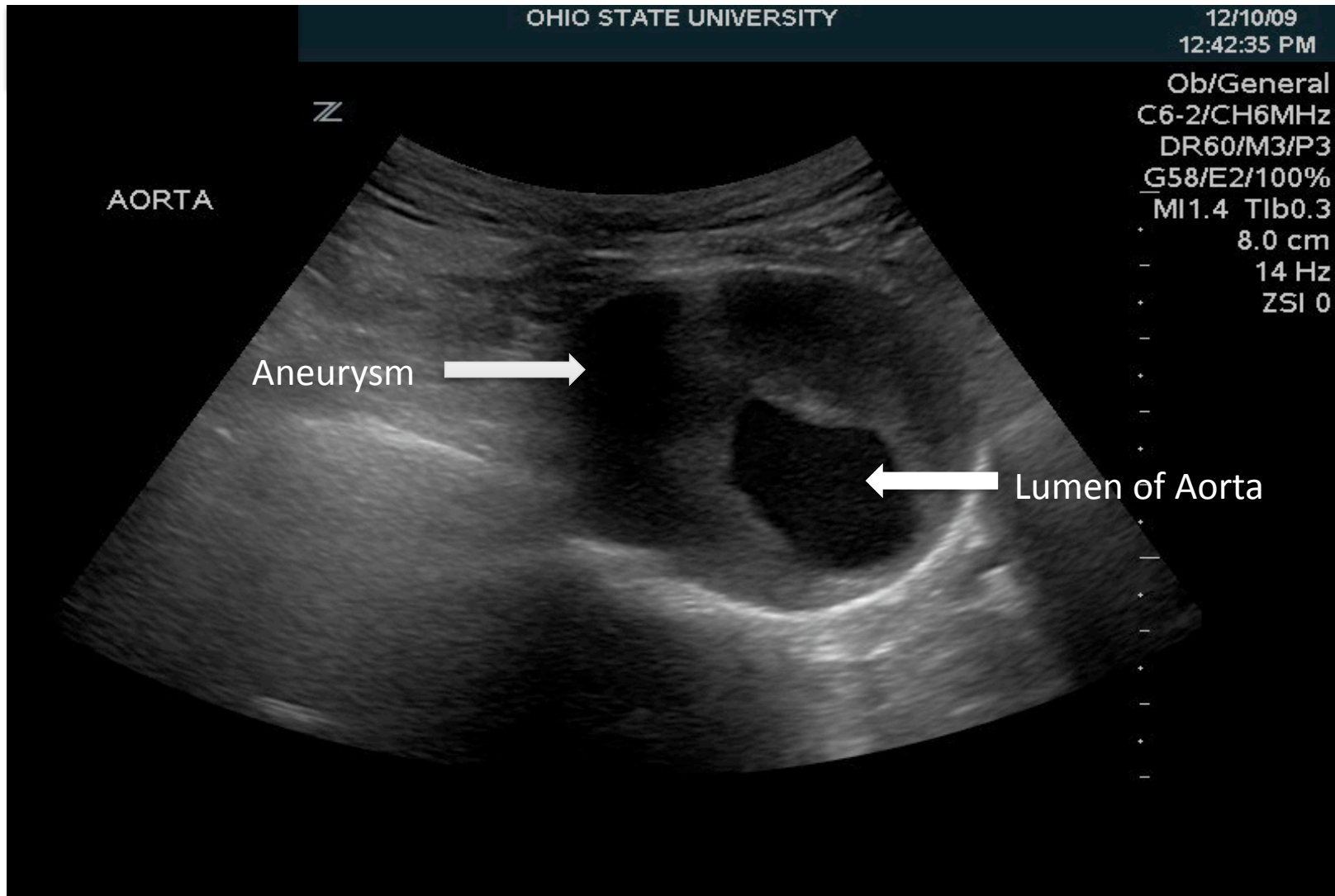


Note: Aorta should be measured from outer wall to outer wall for evaluation of AAA (>3.0 cm is the lower limit for AAA)

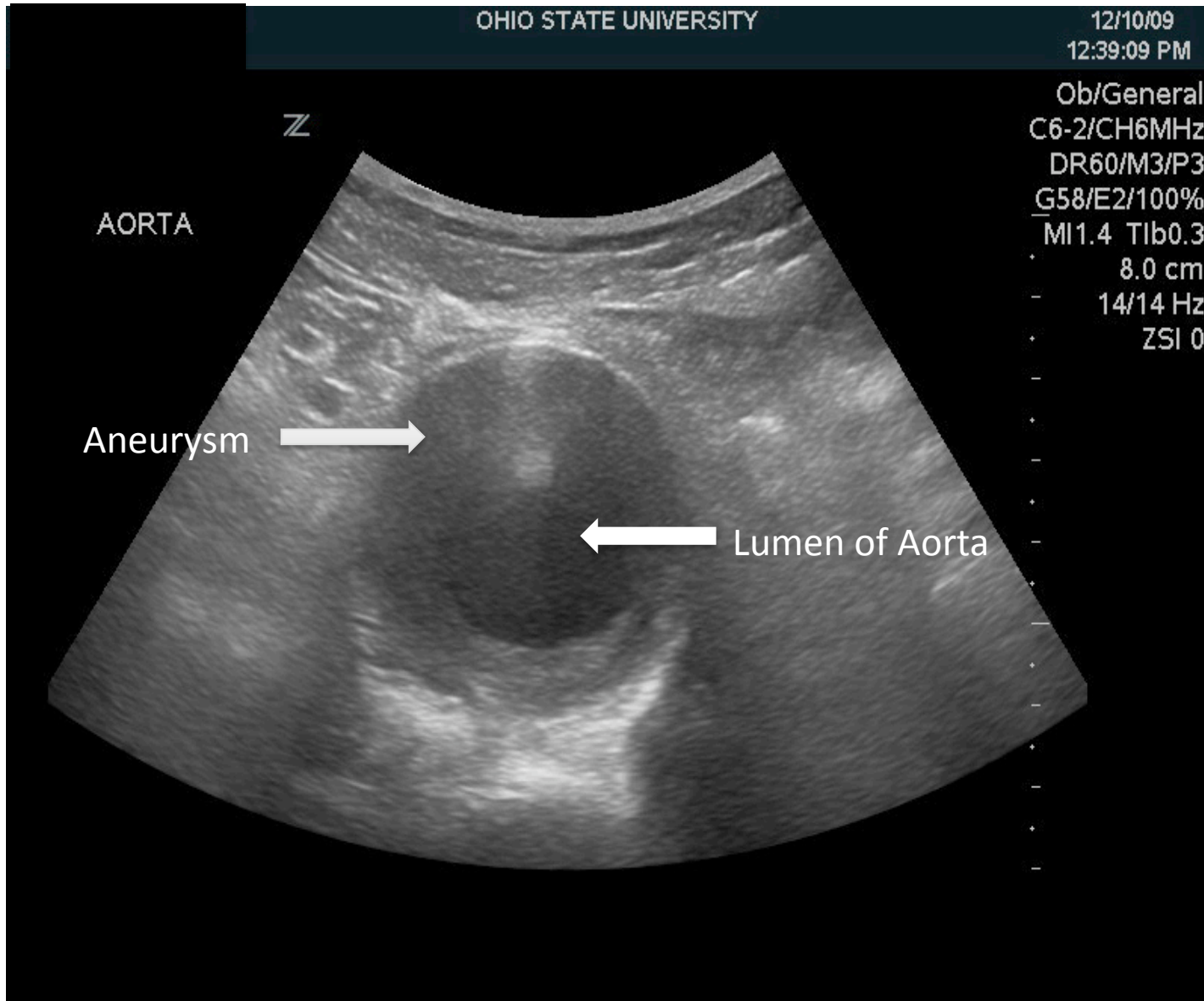
Longitudinal View of AAA



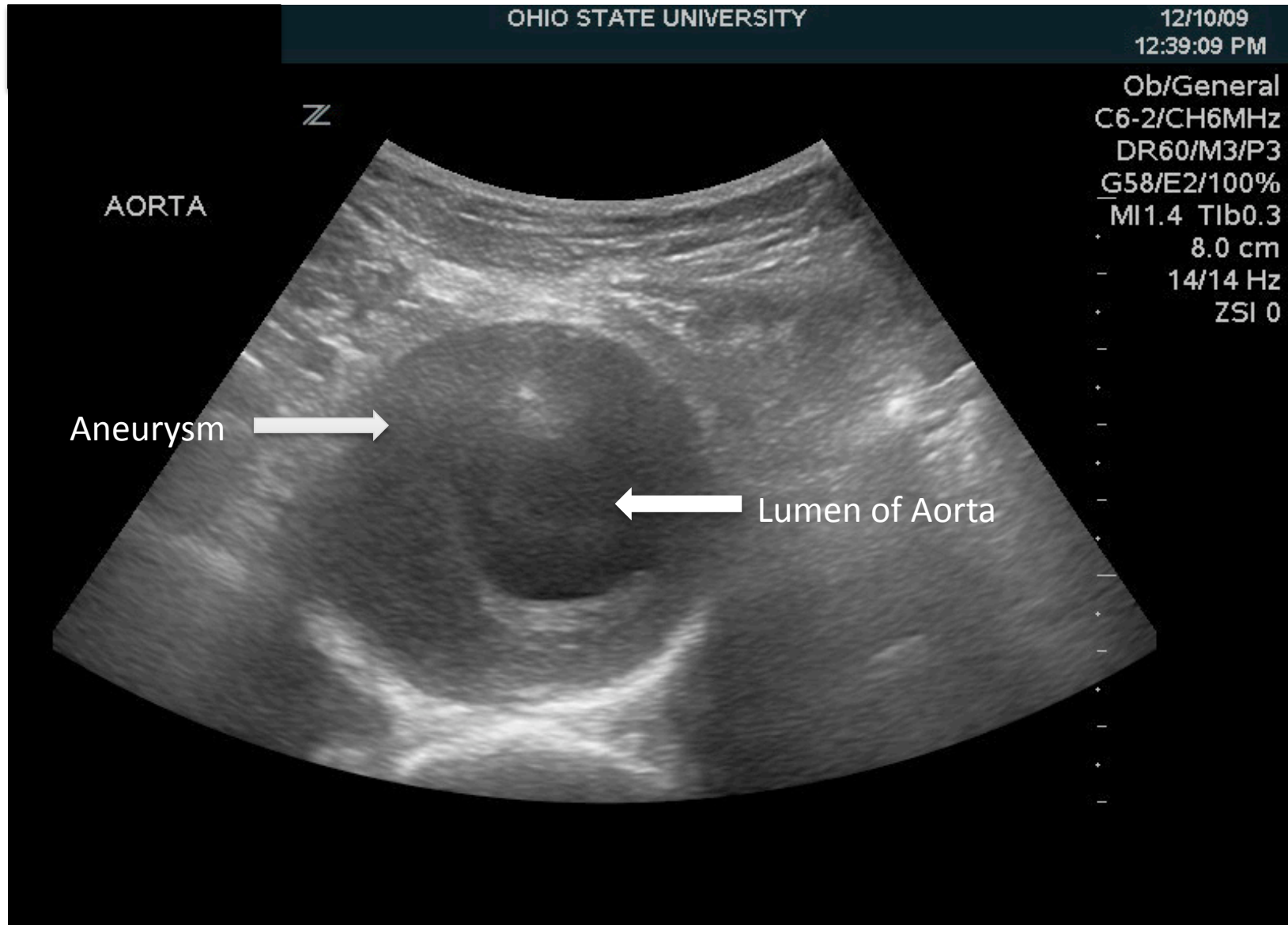
Transverse View of AAA



Transverse View of AAA



Transverse View of AAA



Overview of AAA

Aneurysm: involves all three layers of aorta-
intima, media, and adventitia

> 3.0cm diameter, measured from outer wall to
outer wall

Normal diameter is < 2.3 cm in men and < 1.9
cm in women. Diameter may increase with
age.

Strong association with atherosclerosis

Presentation

- May be asymptomatic until expansion or rupture
 - Sudden and severe abdominal, back, flank, or groin pain
 - Syncope
 - ruptured AAA often presents as shock as: hypotension, , tachycardia, and altered mental status. > 65% of patients with ruptured AAA die from sudden cardiovascular collapse

Risk of Rupture

- Diameter of aneurysm is directly correlated with risk of rupture
- substantial increase in rupture risk as AAA diameter increases from 5 cm to 6 cm
- Independent predictors of rupture: history of smoking, increased initial diameter, COPD, and hypertension.
- Women have higher rates of rupture at smaller diameters.

Guidelines for the treatment of abdominal aortic aneurysms: Report of a subcommittee of the Joint Council of the American Association for Vascular Surgery and Society for Vascular Surgery
David C. Brewster, Jack L. Cronenwett, John W. Hallett, K.Wayne Johnston, William C. Krupski, Jon S. Matsumura;
Journal of Vascular Surgery; May 2003 (Vol. 37, Issue 5, Pages 1106-1117)

Surgical Treatment

- 5.5 cm is threshold for repair in most patients, unless rapid expansion (>0.5 cm/year) or patients become symptomatic
- Elective intervention at 4.5 cm to 5.0 cm is indicated in women.
- Endovascular repair (EVAR) vs. standard open repair
 - EVAR-lower mortality and morbidity but also with higher late complications and reintervention rates

Guidelines for the treatment of abdominal aortic aneurysms: Report of a subcommittee of the Joint Council of the American Association for Vascular Surgery and Society for Vascular Surgery

David C. Brewster, Jack L. Cronenwett, John W. Hallett, K.Wayne Johnston, William C. Krupski, Jon S. Matsumura; Journal of Vascular Surgery; May 2003 (Vol. 37, Issue 5, Pages 1106-1117)

Medical Management

- Risk factor modification
 - Smoking cessation
 - Hypertensive management-Beta blockers
 - Hypercholesterolemia management-HMG-CoA reductase inhibitor (statins)
- Follow up
 - AAA > 4.0 cm should be monitored for rapid expansion (>0.5 cm/year) or an increase in size to 5.5 cm or larger
 - U/S interrogation or CT scanning every 6 months

Patient's hospital course

Presyncope-The patient was found to be orthostatic by vital signs. He was given IV fluid hydration and had resolution of symptoms. Cardiovascular workup included: negative serial troponins, normal AICD interrogation, and stable AAA (which continued to be medically managed)

Intraventricular hemorrhage-Noncontrast head CT that showed an intraventricular hemorrhage in both the right and left lateral ventricles, R >L. Repeat CT x 2 did not show any progression of hemorrhage. He did not develop any focal neurological changes. Aspirin/Plavix were held.

The patient was discharged on home medications (except aspirin and Plavix) and with home nursing to provide intravenous hydration as needed.